



CASE REPORT

TNI Died While Serving Disciplinary Punishment

Bartimeus Nicomama Hutabarat¹, Asan Petrus^{2*}, Nasib Mangoloi Situmorang³

^{1,2,3}Department of Forensic and Medicolegal, Faculty of Medicine, University of Sumatera Utara

Abstract:

Introduction: at the end of February 2020 the big family of the Dawolo Nias clan was shocked by the news that Tulus Sahputra Dawolo, a member of the Special Raider Infantry Battalion 136 / Tuah Sakti Kodam XVI / Pattimura Ambon, died while serving a disciplinary sentence. The victim's body was returned to Nias and buried in the family cemetery, but the family suspected that the cause of the victim's death was unnatural because the family saw a photo of the victim during his lifetime which showed his body was covered with bruises. Finally the family reported the matter to the Military Police of the XVI / PATTIMURA REGIONAL COMMANDO. In accordance with the KODAM XVI / Pattimura Military Police investigator's letter number R / 68 / III / 2020 dated March 9, 2020, on March 12, 2020, the graves of the victims were carried out.

Case Report: It was reported that a male victim, the initials TSD, a member of the Army, Yonif RK 136 / Tuah Sakti Ambon unit, died while serving a disciplinary sentence on Saturday, February 29, 2020 at around 14:48 WIT by a Puskesmas officer. The victim was buried on March 7, 2020 in Nias. The family suspected that the victim died as a result of mistreatment while serving a disciplinary sentence, so the case was reported to the police. So on March 12, 2020, an exhumation and autopsy of the body was carried out according to a written request from the XVI / PATTIMURA MILITARY POLICE REGIONAL COMMAND, Number: R / 68 / III / 2020, 9 March 2020.

Result: The victim found bruises on the stomach, abrasions on the head, forehead, eyelids, chin and blood infiltration on the inner scalp and on the right side of the stomach, bleeding under the thin membrane of the brain. There were stitches found in the crease of the right elbow. Investigations (anatomical pathology) of dams almost all organs. The Criminalistic Laboratory examination did not find any raw material for gasoline.

Discussion: Based on the history of the investigator who immediately saw the victim shortly after the victim died, bruises were found all over the victim's body, this is also in accordance with the notification of the family when asked by showing a photo of the victim with bruises on her back before she died. So from the history and forensic examination of the victim's death as a result of the torture he experienced, which caused bleeding under the thin membrane of the brain.

Conclusion: From the results of external and internal examinations as well as supporting examinations it is concluded that the cause of death of the victim was blunt trauma to the head which resulted in bleeding under the thin membrane of the brain.

Keywords: Blunt Trauma, Subarachnoid Hemorrhage

INTRODUCTION

The death of members of the TNI in recent work has been heard a lot, in February 2020 the extended family of Dawolo Nias was shocked when they heard the news that private officer Tulus Sahputra Dawolo, a member of the Special Raider Infantry Battalion 136/Tuah Sakti Kodam XVI/Pattimura Ambon died while serving a disciplinary punishment. The victim's body was returned to Nias and buried in the family cemetery, but the family suspected the cause of the victim's death was unnatural because the family saw a photo of a life victim showing his body full of bruises. Finally, the family reported the matter to the XVI/PATTIMURA MILITARY REGIONAL POLICE. In accordance with the letter of the KODAM XVI/Pattimura Military Police investigator no.R/68/III/2020 dated 9 March 2020 then on March 12, 2020 an exhumation of the victim's grave was carried out.

Exhumation is the excavation of the grave, which takes back the body that has been buried from his grave. In our country, there is often a report about a murder incident that is too late to be submitted to investigators, so that it can cause

difficulties, both for the investigator and for the doctor to carry out their duties to examine the body because the victim has been buried.

The delay in reporting a suspected incident/death can be caused by various factors, for example due to blindness to the law, transportation problems, witnesses under pressure/threats and incorrect assumptions about the previous post-mortem.⁽⁶⁾(there is a suspicion of incorrect reporting).

In a criminal case that causes trauma to the victim, the doctor is expected to find abnormalities that occur in the victim's body. In the case of a death toll, the doctor is expected to explain the cause of death concerned, how the mechanism of death occurred, assist in the estimation at the time of death, as well as the estimated manner of death.¹

SUBARACHNOID HEMORRHAGE

Subarachnoid hemorrhage is an event of a process of breaking up blood vessels in a space that is under arachnoid

(subarachnoid) caused by a pathological process. Subarachnoid hemorrhage is characterized by blood extravasation to the subarachnoid cavity, the cavity between the inner layer (piamater) and the middle layer (arachnoid matter) which is the part of the membrane that encloses the brain (meninges).²

Subarachnoid hemorrhage occupies 7-15% of all cases of Cerebrovascular Disorders. The prevalence of subarachnoid hemorrhage can reach up to 33,000 people per year in the United States. Approximately 62% first appear at the age of 40-60 years. And if the cause is AVM (arteriovenous malformation) then the incidence is more frequent in men than women.² There are 5 most common causes of subarachnoid hemorrhage, and they are divided into 2 major groups, namely those caused by trauma and those not related to trauma. The causes include:

1. Nontraumatic:

- a. Rupture of an aneurysm in an artery supplying the brain
- b. Intracerebral hemorrhage due to stroke entering the subarachnoid

2. Traumatic:

- a. Direct trauma to the focal region which eventually causes subarachnoid hemorrhage
- b. Facial or neck trauma with fractures in the cervical spine causing tearing of the vertebral artery
- c. Tearing of one of the thin-walled arteries at the base of the brain resulting from sudden hyperextension of the head.

Weak and swollen arteries, as in aneurysms, are very fragile in walls compared to normal arteries. As a result, even minor trauma can cause rupture of the aneurysm resulting in flooding of the subarachnoid space with blood and eventually leading to serious dysfunction or even death.

The puzzle for forensics is whether it was trauma that caused the rupture of an existing aneurysm, or whether someone experienced a headache first as a result of the aneurysm rupturing causing behavioral disturbances in the form of fighting behavior that led to trauma. Another example, whether a person who falls from a certain height causes the aneurysm to rupture, or the person first ruptures the aneurysm causing a subarachnoid hemorrhage and eventually loses consciousness and falls. In some cases, careful investigation coupled with a careful autopsy can solve the puzzle.

Localized mild subarachnoid hemorrhage results from pressure against the head accompanied by shock to the brain and its covering within the skull. This pressure and shock causes tearing of the small blood vessels in the subarachnoid layer, and is generally not a major haemorrhage. If no other aggravating factors such as poor blood clotting ability are found, this bleeding can tell or reveal the pressure of trauma that has occurred to the head. Rarely, a slap to the side of the head and neck can result in a fracture of the lateral process of one of the superior cervical vertebrae. Because the vertebral arteries pass above the lateral processes of the vertebrae in the neck region, fractures in this area can result in tearing of the artery causing massive bleeding which usually penetrates into the subarachnoid layer at

the top of the spine and eventually pooling of the subarachnoid space with blood. Upward blood flow increases and the hemorrhage extends to the base of the brain and lateral to the cerebral hemispheres. In some cases, this condition is difficult to distinguish from non-traumatic bleeding that may be caused by aneurysm rupture.

The type of traumatic subarachnoid hemorrhage that will be discussed this time is a massive type of bleeding. This hemorrhage involves the base of the brain and extends to the lateral side of the brain so that it is similar to bleeding associated with an aneurysm of a large artery at the base of the brain. However, on careful examination, no aneurysm was found, while the vertebral artery remained intact. The cause of the bleeding is thought to be due to the rupture of thin-walled blood vessels at the bottom of the brain, and there is no aneurysm. There is 2 pieces of evidence, though not always available, to support the notion that these events were purely trauma-initiated. The first evidence is a history of sudden hyperextension movements in the head and neck region, which can later lead to collapse and even death..

CASE REPORT

A case was reported of a man, who died on the second day after the victim had previously received training at Pos Kout. On the day of the incident on February 28, 2020 at around 10.30 WIT, on the instructions and orders of the Task Force so that the victim was fostered at Pos Kout, at around 16.30 WIT, the victim arrived at the Waipirit port. Then Pratu 3

Tulus Saputra Dawolo was checked for tension with the result of 140/80, the victim carried out the tradition of running from Waipirit port to Pos Kout, a distance of about 4.6 Km accompanied by several Pos Kout personnel..

At around 21.30 WIT the victim was whipped with a green compressor hose several times in the back, after which he was ordered to rest. And around 23.00 s.d. 24.00 WIT. The victim was again subjected to disciplinary action, after being ordered to rest again at KSA Battalion RK 136/TS;

On Saturday, February 29, 2020 at around 06.00 the victim along with 17 other people will carry out physical training in the morning about 10 km away, previously tension was carried out by the Task Force Team of Health and supervised by 2 supervisors. However, because the victim was not strong anymore and then walked back towards the Pos Kout, while walking the victim saw a retail gasoline seller and took a plastic bottle of mineral water filled with gasoline and drank it immediately, seeing this the supervisor immediately prevented him by grabbing the bottle, then the victim was taken by the supervisor headed to the Pos Kout, upon arrival at the Pos Kout the Battalion Doctor gave medical treatment.

At around 13.15 WIT the victim along with 17 personnel preparing to do the afternoon run, before the afternoon run, the Task Force Team did not check blood pressure and on the order of the suspect to tie the victim's body using a repling rope to the bodies of friend 1 (on the right) and friend 2 (on the left), then the victim and other personnel warmed up and at 13.30 WIT an afternoon run was carried out with

a distance of 5 Km and a backpack weight of 5 Kg, but after a distance of 300 meters the victim fell still trying to continue with the support, suddenly the distance of 400 meters the victim fell again and unconscious and then picked up by his colleagues to the Kout Post, after which the victim was treated by a doctor. Because the victim's pulse was getting weaker, so the doctor evacuated him to the Kairatu Health Center and at around 14:48 WIT the victim was declared dead by the Puskesmas.

According to information from the victim's family, he was buried on March 7, 2020 in Teluk Belukar Cemetery next to the victim's house. Because the family suspected that the victim's death was related to elements of previous persecution, the family finally reported it to the XVI/PATTIMURA MILITARY REGIONAL COMMANDA Military Police and asked for a forensic medical examination on March 12, 2020.

So on March 12, 2020 an exhumation and autopsy were carried out according to a written request from the XVI/PATTIMURA MILITARY POLICE REGIONAL COMMANDO, Number: R/68/III/2020, March 9, 2020.

RESULTS

A. Grave Identification

- A light brown mound was found with a mound height of 30 cm, length 200 cm width 90cm.



- A gravestone of white cross-shaped wooden material with a length of 150 cm wide 60 cm bearing the words "PRATU TULUS SAPUTRA DAWOLO, OMASIDOMOFANODOBASOD OKHOKERISO, FIL.1:23, Born 22-05-1995, Died 29-02-2020 "

B. External Examination

Signs of death: A further decay process is found : found whole body swollen, black skin on the head and neck, part of the chest, upper limbs that peel easily, some white. On soft touch, rattling, hair is easily pulled out and smells bad.

Head: Blister 1 was found on the top of the head with a length of 4 cm and a width of 2 cm along the midline of the body with a distance of 4 cm from the right front hairline and 14 cm from the left ear. Blister 2 was found on the top of the head with a length of 3 cm, a width of 2 cm along the midline of the body with a distance of 8 cm from the front hairline and 15 cm from the left ear..



Forehead: Blister 1 was found on the right forehead with a length of 1 cm, a width of 1 cm with a distance of 1 cm from the midline of the body and 5 cm from the right eyebrow. Blister 2 was found on the left forehead with a length of 0.2 cm, a width of 0.3 cm with a distance of 4 cm from the midline of the body and 4 cm from the left eyebrow..



Eyes: A blister was found in the corner of the right lower eye with a length of 2.5 cm, a width of 1 cm with a distance of 3 cm from the midline of the body and 7 cm from the right ear.. Mouth: A blister was found in the upper right corner of the lip with a length of 1 cm, a width of 0.5 cm, a distance of 6 cm from the midline of the body and 0.5 cm from the corner of the right lip.

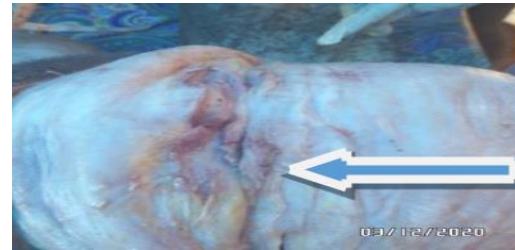Chin: A blister was found on the left chin with a length of 2 cm, a width of 0.5 cm, a distance of 5.5 cm from the midline of the body and 10 cm from the left ear.

A blister was found on the left chin with a length of 1.5 cm, width 0.3 cm with a distance of 2 cm from the midline of the body and 5 cm from the corner of the left lip. There were no signs of fracture.

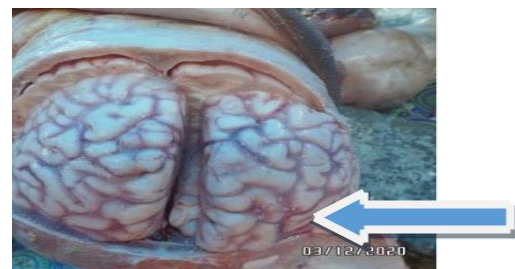

C. Internal Examination

Head : At the opening of the scalp, blood infiltration was found with a length of 8 cm, a width of 3 cm on the skin of the inner forehead at the midline of the body and 10 cm from the right ear. No skull fracture was found.

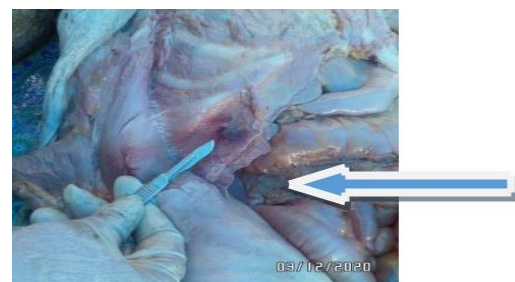


At the opening of the thick membrane of the brain found blood infiltration under the thin membrane of the brain on the entire surface of the brain



Stomach: At the opening of the abdomen found fat thickness of 1 cm.

Blood infiltration was found in the right abdomen with a length of 3 cm and a width of 3 cm with a distance of 9 cm from the midline of the body and 24 cm from the crease of the right thigh.



D. Supporting Examination

Laboratory examination Pathology Anatomy In general, tissue lysis, interstitial bleeding was also seen in the thick membranes of the brain accompanied by congestion in almost all organs. Toxicological examination: stated:

No fuel oil (BBM) Hydrocarbon type gasoline was found.

DISCUSSION

It was reported a case of a male victim, the initials of TSD, a member of the TNI AD unit Yonif RK 136/Tuah Sakti Ambon, died on Saturday, February 29, 2020 at around 2:48 p.m. WIT by a Puskesmas officer. The victim was buried on March 7, 2020 in Nias. In accordance with the letter from the Military Police investigator KODAM XVI/Pattimura no.R/68/III/2020 dated March 9, 2020, on March 12, 2020 at 11.00 WIB, an exhumation was carried out on the graves of the victims. Based on the anamnesis from the family, the day before the victim died, the family received information from the victim by telephone that the victim was undergoing disciplinary sanctions at the post office and the victim said that she could hardly bear the sanctions. After the victim was buried, the family received information through photos and videos that the victim had been abused. Based on the anamnesis from the investigators, it was confirmed that the victim was indeed undergoing disciplinary sanctions. The family and investigators suspect that the victim died as a result of abuse during the disciplinary action. From a forensic point of view, if the victim has been buried, then the decomposition process will occur and will eliminate evidence such as trauma that occurred on the victim's body. So it requires a more thorough examination, but if the decay process has advanced then even with a careful examination the injury or trauma that occurred will still not be found. We hope that every victim of a crime or suspected of having a criminal

element in the cause of death, so that an autopsy is carried out before the victim is buried. We hope that investigators, both POLRI investigators and MILITARY POLICE investigators, will heed the KAPOLRI's instructions No. Pol.:Ins/E/20/IX/75 dated 19 September 1975 regarding the application/revocation of Visum et Repertum points 3 and 10 reads:

Point 3: In the event that someone who suffered from the wound before finally died, he must immediately submit a follow-up letter to request a Visum et Repertum for the corpse, meaning that the corpse must be surgically removed. There is absolutely no justification for the request for a Visum et Repertum on a corpse based on external examination alone.

Point 10: In the event that the injured person or the corpse is an ABRI, to request a Visum et Repertum, one should contact the local MILITARY POLICE from the victim's unit.

Based on the instructions above, we hope that the POLICE and MILITARY POLICE will pay more attention when handling cases of criminal acts of death victims including the families of the POLICE and TNI because if the POLICE and TNI as part of law enforcement agencies and families do not respond to these instructions and do not understand the intention and purpose of the autopsy so that the autopsy was not performed, what about the general public who do not understand the intention and purpose of the autopsy itself, besides there is a misunderstanding about autopsy where at autopsy there is a kind of organ harvesting for certain purposes. So that currently in

forensic medicine services when dealing with victims of death crimes, there are still many victims who are only examined externally which of course will provide very limited information related to the settlement of legal cases of the victim.

On examination, the whole body was swollen, the skin was black on the head and neck, parts of the chest, upper limbs, some were white and easily peeled off, on soft touch, the hair creaked easily, the back was found to be loose tissue due to decay, it was suspected that the back area had more trauma so that the decomposition process is faster. This foul smell indicates that the victim has undergone a process of advanced decomposition because previously the victim had been buried and the examination was carried out 12 days after the victim died and 5 days after being buried. Although previously this victim has been formalized

There were abrasions on the top of the head, on the right and left forehead, on the right lower corner of the eye and bruises on the right side of the abdomen. No signs of resistance or self-defense were found, possibly because the victim was undergoing disciplinary sanctions by his superiors so that the victim was powerless to fight back. As evidence of the violence experienced by the victim by other people, violence is usually found in inaccessible areas such as the back, waist, but this victim is not found because of the process of decay. We have tried to get the victim's external examination report through the investigator, but the investigator was unable to provide the report because the investigator did not have the report at the time and the report was in the hospital in Maluku. Based on the results of the

examination of the trauma experienced by the victim, we believe that the trauma was carried out by someone else.

Sutures were found in the skin in the crease of the right elbow, suspected to be trauma after the victim died for the process of treating the corpse (corpse formalin action).

Blood infiltration was found at the opening of the scalp, at the opening of the thick membrane of the brain, blood was found under the thin membrane of the brain and on the entire surface of the brain. Based on the results of the examination above, the victim suffered a blow that caused the rupture of a blood vessel. Rupture of blood vessels causes the body to compensate by constricting blood vessels. Constriction of the blood vessels causes fluid to leak out of the blood vessels and causes brain oedema. As a result, pressure occurs in the head cavity either due to edema or blood fluids resulting in pressure on the brain stem. Emphasis on the brain stem results in disturbances in the function of organs that cause the victim to die.

Anatomy pathological examination results: generally tissue lysis. Tissue lysis is due to the decay process. This is something we really don't expect, which can be prevented if the victim is autopsied before undergoing the process of decay or before the victim is buried. Toxicological examination results: No gasoline type hydrocarbon fuel was found. This examination was carried out because based on the investigator's anamnesis, the victim drank gasoline as well as the victim had been formalized and underwent a decay process so that the forensic examination was difficult to detect, so to

confirm the presence of these substances in the victim's body, we requested assistance from the POLDASU forensic laboratory examination.

LEGAL REVIEW

Based on the results of the family history, investigators and autopsy as well as supporting examinations, it is believed that the victim experienced violence by someone else. The violence experienced by the victim was blunt trauma which resulted in the victim's death. In this case, the suspect can be subject to a violation of the KUHP article 351 paragraph 3 with a maximum imprisonment of *seven years*. However, it is also possible to be prosecuted for violating KUHP article 338 with a penalty of *fifteen years* in prison.

CONCLUSION

The victim was found with bruises on the abdomen, abrasions on the head, forehead, eyelids, chin, and blood infiltration on the inside of the scalp and on the right side of the abdomen, bleeding under the thin membranes of the brain due to blunt trauma. Sutures were found in the skin in the crease of the right elbow, allegedly due to actions related to the treatment of the corpse. Anatomical pathology laboratory examination results found dams in almost all organs. From the results of external and internal examinations as well as supporting examinations, it was concluded that the cause of death of the victim was blunt trauma to the head which resulted in bleeding under the thin membrane of the brain resulting in an increase in pressure in the head cavity, so that the brain was pushed into a large hole in the skull

causing the brainstem to be compressed which caused disruption of all organ function that causes the victim to die.

SUGGESTION

In order for the forensic examination of cases of victims of the death penalty to be better, it is necessary to carry out an autopsy before the victim is buried. However, they often face obstacles/don't get approval from certain families or communities. So it is necessary to carry out future socialization / counseling about autopsies to the wider community.

BIBLIOGRAPHY

1. Amir A, : Kapita Selekt Kedokteran Forensik, FK-USU, Medan;1995:pp.57-62.
2. Chadha P.V, : Ilmu Forensik dan Toksikologi , Alih bahasa Johan Hutauruk, Widya Medika, Jakarta;1975:pp.
3. Hamdani N, : Ilmu Kedokteran Kehakiman, Edisi Kedua, PT. Gramedia Pustaka Utama, Jakarta;1992:p.44-7.
4. Idries AM, : Pedoman Ilmu Kedokteran Forensik, Edisi Pertama, PT. Binarupa Aksara, Jakarta, 1989, pp.254 - 6.
5. Knight B, Arnold, : Simsons Forensic Medicine, 11th Edition, Oxford university Press. Inc, New York - USA;1997:p.19.
6. ModiNJ, : Medical Jurisprudence and Toksikologi, 18th Edition, Bombay - India, 1972, pp.88-90.
7. Nandy A, : Principles of Forensic Medicine, New General Book

- Agency (P) Ltd, Calcuta India;1995:p.184.
8. Parikh C.K, : Parikhs textbook of Medical Jurisprudence and Toxicology, Medical Publication, Bombay – India;1979:pp.126–8
 9. Arif Budiyanto, dkk. Ilmu kedokteran forensik. Jakarta: Bagian Kedokteran Forensik FKUI, 1997; hlm.2, 214-218
 10. Gonzales TA, et al. Legal medicine : pathology and toxicology. Appleton Centuries Crofts, Inc : New York, 1996 : hlm 122-124, 132-133
 11. Dahlan S. Ilmu kedokteran forensik : pedoman bagi dokter dan penegak hukum. Badan Penerbit Universitas Diponegoro. Semarang, 2000 : 48
 12. Sheperd, Richard. Simpson's forensic medicine. 12th editionm. Greaat Britain: Arade Publisher, 2003; page 120, 124-125
 13. Hall & Guyton. Buku Ajar Fisiologi Kedokteran. Edisi 9. Jakarta, 1997 : EGC ; hlm. 706-707
 14. Knight. B, forensic Pathology. Second edition. Oxford university press, inc : New York, p 506 - 507
 15. Mardjono Mahar Prof. DR dan Sidharta Priguna. Prof.DR. Neurologi Klinis Dasar. Edisi 6. Dian Rakyat : Jakarta, 2007 : 439
 16. DiMaio, Vincent, Dominick DiMaio. Forensic pathology. 2nd edition. New York:CRC Press LLC, 2001