

Right-sided infective endocarditis with pulmonary thromboembolism in a patient with end-stage renal failure

Dr. Rodolfo Vega Candelario

Cardiology Department, Hospital General Docente Roberto Rodríguez Fernández Morón, Ciego de Ávila
Cuba

Abstract:

Right-sided infective endocarditis is a serious issue to be addressed due to its different forms of presentation and, above all, to the use of greater and better medical procedures that require central venous accesses. Such procedures are important and effective, but constitute a risk factor at the same time; leading to cardiac events with their harmful effects that threaten the patient's life. Bacterial resistance to treatment and their appearance in immunosuppressed patients are factors that worsen prognosis. We report the case of a 28-year-old man with a history of end-stage renal failure presenting right-sided infective endocarditis with pulmonary thromboembolism.

Keywords: Infective endocarditis, Chronic kidney disease, Cardiogenic embolism Endocarditis infecciosa de corazón derecho con troboembolismo pulmonar en paciente con insuficiencia renal terminal

Introduction

The classic clinical presentation of the infective endocarditis (IE) has varied over the past 50 years, because most of the patients receive incomplete or partial antibiotic treatment contributing to delay the diagnosis¹⁻³. Currently, fever, recurrent bacteremia, heart failure and systemic embolization Vega Candelario R. CorSalud 2018 Jul-Sep;10(3):256-260 257 are the most common manifestations of peripheral hypersensitivity, splenomegaly and appearance of a new murmur of valvular failure³⁻⁵. Nevertheless, the presence of fever, cardiac murmur and positive blood culture grant a high suspicion to this disease.

The right heart IE mainly involves the tricuspid valve, the pulmonary location is rare, and it is frequently caused by yeast, pseudomonas and other negative gram bacteria previously unusual; which, by location and type of germ, differ from streptococcal or staphylococcal endocardial infections^{5,6}. The use of intravenous drugs and prolonged venous catheterization are important risk factors⁷.

The diagnosis of right IE will have a high index of suspicion in patients using intravenous drugs or who need prolonged placement of venous catheters, pre-sent fever and pulmonary infiltrates detected on the chest radiography. Pneumonia or pulmonary embolism may present in 70-100% of the cases and a murmur of tricuspid regurgitation is frequent; in addition, up to 20% of patients may have negative cultures⁵⁻⁷.

Case Report

Here is presented the case of a 28-year-old Caucasian man, 41 kg, with a history of chronic kidney disease (CKD) since the first months of life (severe congenital bilateral renal atrophy), which was in end-stage and received a kidney transplant from a living donor (sister), that complicated by a thrombosis of the implanted

Dr. Rodolfo Vega Candelario / Right-sided infective endocarditis with pulmonary thromboembolism in a patient with end-stage renal failure

kidney and triggered the failure of the transplant; hence, he rejoined the hemodialysis program (for venous catheter), waiting for a new transplant.

After one of the programmed hemodialysis, the patient presented fever of 38°C and chills, thus he was admitted at the hospital for study and treatment; the central venous catheter was removed and blood cultures were indicated.

Physical examination

Moist and hypo pigmented mucous membranes. Vesicular murmur diminished, without rattles. Rhythmic heart sounds, with systolic murmur II/VI in low left sternal border and positive Rivero Carballo maneuver (increase in intensity during inspiration). Heart rate of 108 beats per minute and blood pressure of 200/110 mmHg. The funduscopy was normal and the assessment of radiocephalic and brachiocephalic arteriovenous fistulas of the left arm showed the possibility of access for the next hemodialysis and treatment administration.

After taking several samples for blood culture, the antibiotic treatment (cephalosporin's and aminoglycosides) was started with dose adjustment for CKD; but 48 hours after admission, the patient still had fever with severe chills and poor general condition.

Evolution

During the evolution, he presented persistent cough, difficult to control, accompanied by severe pain in the chest and back, which described "like being stubbed", and abundant expectoration with red blood, shining, dyspnea, orthopnea, cyanosis, profuse sweating, extreme anxiety and a sense of impending death; as well as hepatomegaly, jugular engorgement and edema in lower limbs. In addition, hemodynamic instability with arterial hypotension, tachycardia of 184 beats per minute, peripheral hypo saturation of oxygen and respiratory distress; by all which the endotracheal intubation and mechanical artificial ventilation were the decisions made at the moment.

The chest radiography (**Figure 1A**) showed images compatible with a pulmonary infarction and the transthoracic echocardiogram (**Figure 1B**) showed the presence of an intracardiac mass (in the right ventricle), in relation to the tricuspid valve, compatible with endocardial vegetation.

In the serial blood cultures grew a multi-resistant golden staphylococcus, which finally responded to the antibiotic treatment combined with vancomycin, aztreonam and tobramycin.

The state of extreme severity of the patient was improved, mechanical ventilation was removed, the presence of other germs discarded, especially fungi, due to the size of vegetation, the blood cultures were negativized and, after 23 days with the anti-biotic treatment, radiological improvement was found (**Figure 2A**) and disappearance of the vegetation (**Figure 2B**).

The antibiotic treatment was maintained for six weeks and the access for the hemodialysis fistulas was reassumed.

Comment

The patient presented had a severe pulmonary thromboembolism from an infective endocarditis of the right heart, stimulated by the central venous Right-sided infective endocarditis with PTE in a patient with endstage CKD

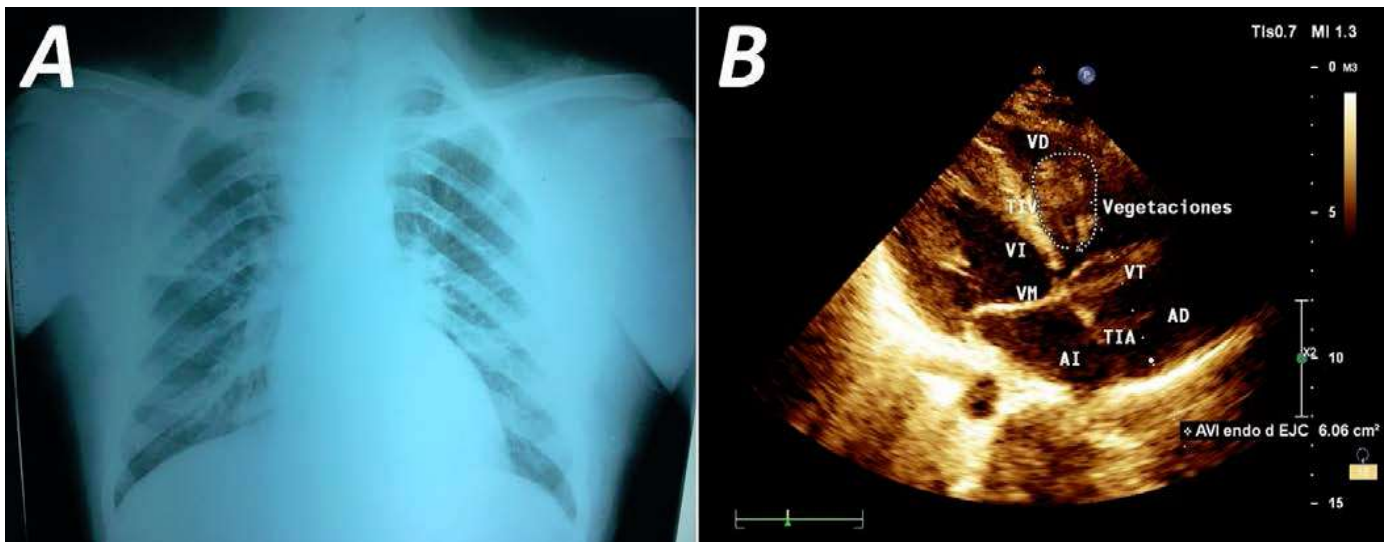


Figure 1. **A.** Posteroanterior chest radiography showing multiple lesions produced by embolic phenomena (possible right pulmonary infarction) due to right heart vegetation. **B.** Echodense image that suggests vegetation in the right ventricular, attached to the tricuspid valve, and severe tricuspid regurgitation. Acronyms in Spanish: *AD*, right atrium; *AI*, left atrium; *TIA*, interatrial septum; *TIV*, interventricular septum; *VD*, right ventricle; *Vegetaciones*; vegetations; *VI*, left ventricle; *VM*, mitral valve; *VT*, tricuspid valve.

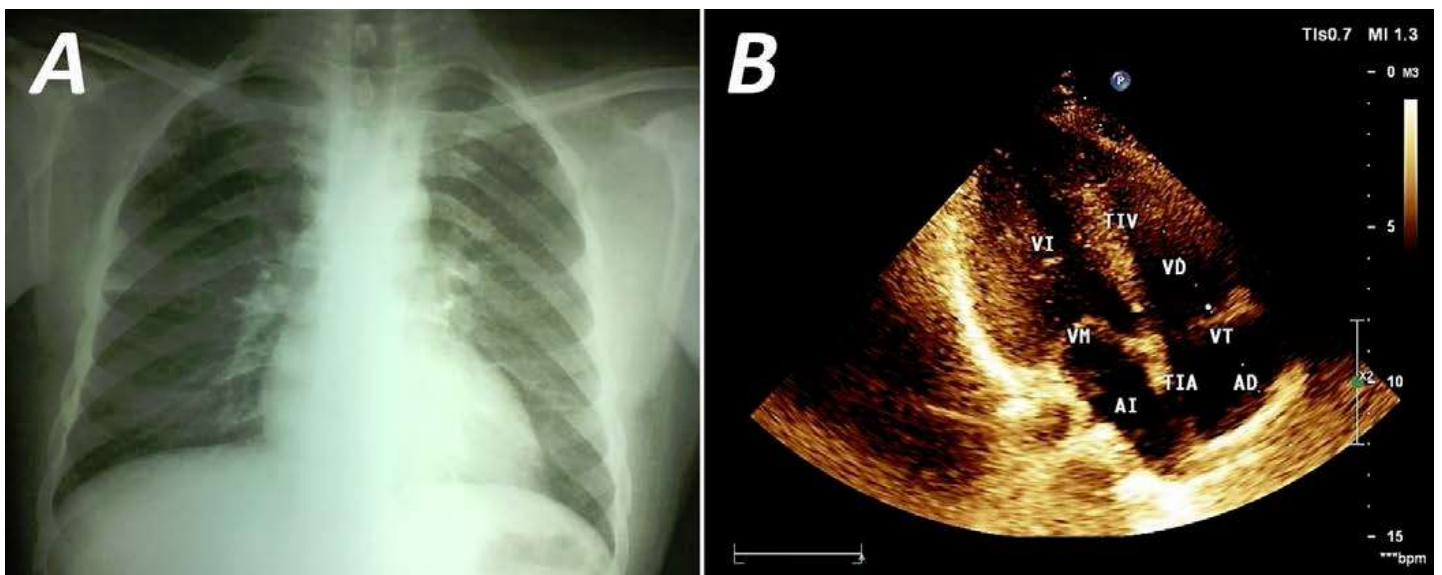


Figure 2. **A.** Posteroanterior chest radiography and **B.** Transthoracic echocardiogram showing improvement of the radio-graphic lesions and disappearance of intracardiac mass, after specific antibiotic treatment. Acronyms in Spanish: *AD*, right atrium; *AI*, left atrium; *TIA*, interatrial septum; *TIV*, interventricular septum; *VD*, right ventricle; *VI*, left ventricle; *VM*, mitral valve; *VT*, tricuspid valve. catheter for hemodialysis, which was used considering that after transplantation, the functionality of arteriovenous fistulas of the upper left member had been lost. The large vegetation is explained for being a patient with immunodeficiency due to the CKD, which favored the proliferation of germ that usually produces large vegetation, as fungi do it In all patients with terminal CKD, dependent on hemodialysis through central venous catheter, the appearance fever should be paid special attention, because intravascular catheters are risk factors for the entry of germs that can colonize the endocardial

Figure 1. **A.** Posteroanterior chest radiography showing multiple lesions produced by embolic phenomena (possible right pulmonary infarction) due to right heart vegetation. **B.** Echodense image that suggests vegetation in the right ventricular, attached to the tricuspid valve, and severe tricuspid regurgitation.

Dr. Rodolfo Vega Candelario / Right-sided infective endocarditis with pulmonary thromboembolism in a patient with end-stage renal failure

Acronyms in Spanish: *AD*, right atrium; *AI*, left atrium; *TIA*, interatrial septum; *TIV*, interventricular septum; *VD*, right ventricle; *Vegetaciones*; vegetations; *VI*, left ventricle; *VM*, mitral valve; *VT*, tricuspid valve.

Figure 2. A. Posteroanterior chest radiography and **B.** Transthoracic echocardiogram showing improvement of the radio-graphic lesions and disappearance of intracardiac mass, after specific antibiotic treatment.

Acronyms in Spanish: *AD*, right atrium; *AI*, left atrium; *TIA*, interatrial septum; *TIV*, interventricular septum; *VD*, right ventricle; *VI*, left ventricle; *VM*, mitral valve; *VT*, tricuspid valve.⁸ Vega Candelario R. *CorSalud* 2018 Jul-Sep;10(3):256-260 259 surface and cause serious complications, endanger-in life

These devices favor IE of the right cardiac structures, which is a frequent cause of thromboembolism and pulmonary infarction, with the possibility of producing hemoptysis¹⁰. Murom et al¹¹ found IE in 76% of patients with central venous catheter. The involvement of the pulmonary valve ranges from 1.7- 2.0%⁶, and it is more frequent in intravenously drug addiction and in patients with congenital heart dis-ease¹⁰⁻¹³. When it affects a healthy heart, the most frequent microorganism is the golden staphylococcus; however, in underlying structural diseases is the viridians streptococcus^{5,13}.

The blood cultures with antimicrobial susceptibility testing are essential for accurate diagnosis and treatment of IE, and the echocardiography remains a sensitive technique for detecting vegetation, alt-Hough the transesophageal mode has the greatest value^{13,14}. The intravenous antibiotics in these pa-tents should be for six weeks^{1,13}, and in the immunosuppressed ones must provide the possible presence of opportunistic pathogens which may be defin-cult to identify with the usual culture means¹⁵. The discovery of new and better antimicrobials has imp-proved the prognosis of these patients, but pharma-ecological treatment is not always enough, hence, there are precise indications for surgery^{1,13,16}.

Several authors have suggested that the presence of fever, heart murmur, positive blood cultures, evidence of pulmonary embolism, septic and absence of systemic embolism, next to the echocardiographic demonstration images compatible with vegetation on the pulmonary valve or tricuspid raise the sensitive-ty and specificity of the right IE's diagnosis^{1,7,10-12,17}.

References

1. Baddour LM, Wilson WR, Bayer AS, Fowler VG, Tleyjeh IM, Rybak MJ, et al. Infective endocardi-tis in adults: Diagnosis, antimicrobial therapy, and management of complications: A scientific state-ment for healthcare professionals from the American Heart Association. *Circulation*. 2015;132(15): 1435-86.
2. Tissières P, Gervaix A, Beghetti M, Jaeggi ET. Value and limitations of the von Reyn, Duke, and modified Duke criteria for the diagnosis of infective endocarditis in children. *Pediatrics* [Inter-net]. 2003 [citado 10 May 2018];112(6 Pt 1):e467- 471. Disponible en: <http://pediatrics.aappublications.org/content/pediatrics/112/6/e467.full.pdf>
3. BinAbdulah AA, Baddour LM, Erwin PJ, Hoen B, Chu VH, Mensah GA, et al. Global and regional burden of infective endocarditis, 1990-2010: a sys-tematic review of the literature. *Glob Heart*. 2014; 9(1):131-43.
4. Cahill TJ, Baddour LM, Habib G, Hoen B, Salaun E, Pettersson GB, et al. Challenges in infective endocarditis. *J Am Coll Cardiol*. 2017;69(3):325-44.
5. Torres Gómez DA, Reales Agón MF, Roa Bernal JA, Alarcón J. Endocarditis bacteriana y embo-lismo pulmonar múltiple como complicación aso-ciada en pacientes pediátricos. *Rev Gastrohnp*. 2015;17(3):S13-6.
6. Ortiz-Bautista C, López J, García-Granja PE, Vila-costa I, Sevilla T, Sarriá C, et al. Endocarditis in-fecciosa derecha en portadores de dispositivos cardiacos: perfil clínico y pronóstico. *Med Clin (Barc)*. 2017;149(11):477-482.

Dr. Rodolfo Vega Candelario / Right-sided infective endocarditis with pulmonary thromboembolism in a patient with end-stage renal failure

7. Vallabhajosyula S, Varma MD, Vallabhajosyula S, Vallabhajosyula S. Right-sided infective endocarditis in an Indian Intensive Care Unit. *J Glob Infect Dis*. 2016;8(3):124-5.
8. Otome O, Guy S, Tramontana A, Lane G, Karuna-jeewa H. A retrospective review: Significance of vegetation size in injection drug users with right-sided infective endocarditis. *Heart Lung Circ*. 2016;25(5):466-70.
9. Di Filippo S. Prophylaxis of infective endocarditis in patients with congenital heart disease in the context of recent modified guidelines. *Arch Cardiovasc Dis*. 2012;105(8-9):454-60.
10. Chahoud J, Sharif Yakan A, Saad H, Kanj SS. Right-sided infective endocarditis and pulmonary infiltrates: An Update. *Cardiol Rev*. 2016;24(5):230-7.
11. Marom D, Levy I, Gutwein O, Birk E, Ashkenazi S. Healthcare-associated versus community-associated infective endocarditis in children. *Pediatr Infect Dis J*. 2011;30(7):585-8.
12. Johnson JA, Boyce TG, Cetta F, Steckelberg JM, Johnson JN. Infective endocarditis in the pediatric patient: A 60-year single-institution review. *Mayo Clin Proc*. 2012;87(7):629-35.
13. Nishimura RA, Otto CM, Bonow RO, Carabello BA, Erwin JP, Fleisher LA, et al. 2017 AHA/ACC Focused Update of the 2014 AHA/ACC Guideline for the Management of Patients With Valvular Heart Disease: A Report of the American College of Cardiology/American Heart Association Task Force on Clinical Practice Guidelines. *J Am Coll Cardiol* 8,9. Right-sided infective endocarditis with PTE in a patient with end-stage CKD *CorSalud* 2018 Jul-Sep;10(3):256-260 *Cardiol*. 2017;70(2):252-89.
14. Bai AD, Steinberg M, Showler A, Burry L, Bhatia RS, Tomlinson GA, et al. Diagnostic accuracy of transthoracic echocardiography for infective endocarditis findings using transesophageal echocardiographic as the reference standard: A meta-analysis. *J Am Soc Echocardiogram*. 2017;30(7):639-646.e8.
15. Begezsan II, Began C, Gibe L, Dorobat CM, Roşu F. Infective endocarditis in non-HIV immunosuppressed patients. *Rev Med Chir Soc Med Nat Iasi*. 2012;116(3):687-91.
16. Raza S, Hussain ST, Rajeswaran J, Ansari A, Trezzi M, Arafat A, et al. Value of surgery for infective endocarditis in dialysis patients. *J Thorac Cardiovasc Surg*. 2017;154(1):61-70.e6.
17. Ajdakar S, Elbouderkou M, Rada N, Draiss G, Bouuskraoui M. Multiple pulmonary emboli complicating infective endocarditis in a child with congenital heart disease. *Arch Pediatr*. 2015;22(4):401-4.