

Glomus tumor is not always digital: case report

Elharrouni Alaoui Aicha, Douhi Zakia, Elloudi Sara, Baybay Hanane, Mernissi FZ

Department of dermatology CHU Hassan II, FES ,Morocco

ARTICLE INFO



Recived article: 12-01-2020

Accepted article: 29-01-2020

Published article: 01-02-2020

Corresponding Author:

Elharrouni Alaoui Aicha

ABSTRACT

Glomus tumors are benign vascular neoplasms that arise from specialized dermal arteriovenous anastomoses called glomus bodies. Glomus tumors most commonly occur in the hand and specifically the subungual region of the distal phalanx. however, a review of the literature suggests that extradigital glomus tumors may occur more often than is generally recognized. A subcutaneous glomus tumor of the forearm is a very rare occurrence and only a few cases have been reported in the literature. we report a 40 year-old man with a 5-year history of a painful subcutaneous nodule of his right forearm. Clinically differential diagnosis was and benign malignant skin tumor. Surgical excision was performed. Histopathological examination, and Immunohistochemistry confirmed the diagnosis of Glomus tumor.

©2020, MCCR, All Right Reserved

Doi: <https://doi.org/10.15520/mcrr.v3i2.86>

Introduction:

MASSON described glomus tumour as a benign neuromyoarterial proliferation. It represents approximately 1% -5% of all tumors of the hand. Pain is the main clinical sign. Definitive diagnosis is based on a body of evidence: clinical and radiological but only histology will allow confirmation. We present a case of a 40-year-old man who presented to our department for a painful subcutaneous nodule on the right forearm. The tumor was surgically excised and revealing glomus tumour.

Case report:

A 40 year-old man visited our department with a 5-year history painful subcutaneous nodule in his right forearm and localized point tenderness. Physical examination revealed a painful mobile nodule, with pigmentation of the surface skin. Palpation elicited a positive Tinel's sign (trigger zone)(figure1). Hildreth's test was positive because there is

reduction in pain after application of a tourniquet proximally on the arm. This nodule was nonspecific and diagnostic considerations included a benign skin tumor or ,glomus tumor, a small peripheral nerve sheath tumor. Additional soft malignant skin tumor could not be excluded. Surgical excision was performed. Histopathological examination revealed the cells were of middle to large size with abundant eosinophilic cytoplasm. The nuclei were round to oval, showing small nucleoli. No necrosis or mitotic activity was observed(figure2 (a+b),and Immunohistochemistry study revealed positivity of AML and negativity of CD68, CD34, CD31 and PS100. On the basis of histopathological examination, and immunohistochemistry final diagnosis of Glomus tumor was given. No recurrence was observed in the 4 months follow-up of the patient.

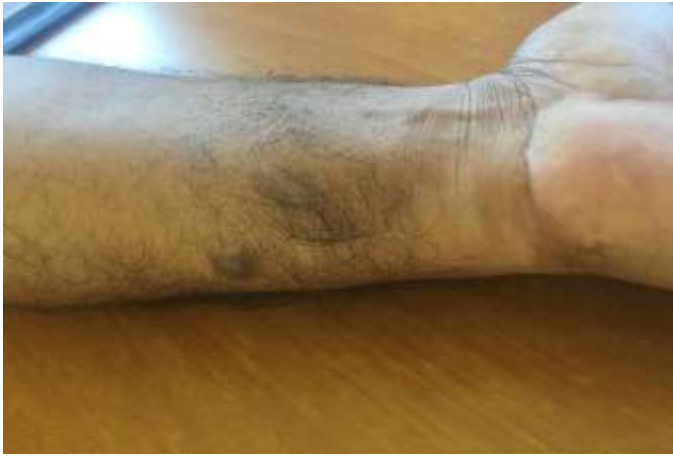

Figure1 : Photograph of a painful nodular subcutaneous lesion with pigmentation of the surface skin of the forearm.

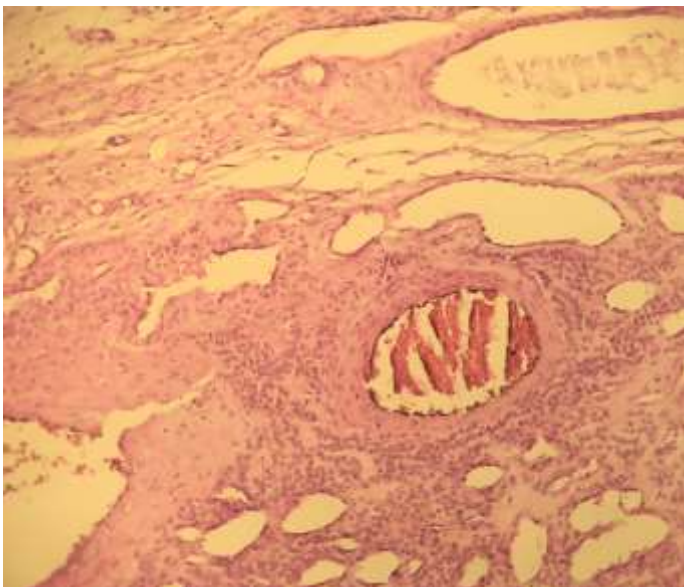
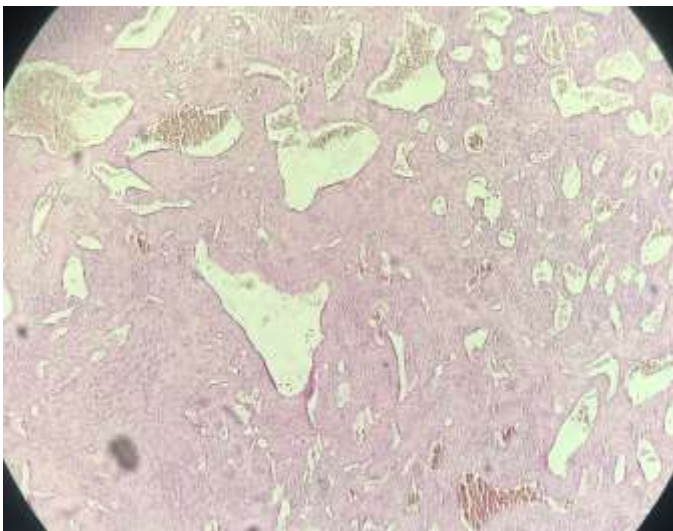


Figure2 : (a+b) : Histopathological examination revealed the cells were of middle to large size with abundant eosinophilic cytoplasm. The nuclei were round to oval, showing small nucleoli and abundant blood vessels. No necrosis or mitotic activity are present. (Hematoxylin- eosin stain 4x and 10x.)

Discussion:

Glomus tumor are benign vascular neoplasms that arise from neuromyoarterial structures in the reticular dermis called glomus bodies. (1) Glomus tumors are rare but majorly benign, accounting for approximately 2% of all soft tissue tumors in the extremities(1-2). These tumors are most often found in the digital pulp and subungual region of the fingertips(1-2). Cases of extradigital glomus tumours found in the forearm have also being reported.(3) The most frequently encountered clinical scenario is a female patient presenting with a painful and thermosensitive nodule in her hand. The typical triad symptoms of glomus tumors are pinpoint pain, rigorous pain, and cold hypersensitivity. Diagnostic tests include Love pin test, Hildreth test, and cold sensitivity test (3-4). Useful imaging ultrasound and magnetic resonance imaging (MRI). Physical examination and imaging studies can help guide management, but definitive diagnosis can be made only through histological examination performed after surgical excision(4).The gold standard of treatment is complete excision, which frequently results in permanent symptom relief. Malignant change is very rare.(5)

Conclusion:

In conclusion, successful diagnosis of forearm glomus tumors requires clinical suspicion given its low incidence and wide differential diagnosis. Only rare cases have been reported who developed glomus tumor on the forearm. Clinical diagnosis of glomus tumor is very difficult and the diagnosis is mainly based on histological features.

Référence:

1. Lancien U, et al. Extradigital glomus tumor of the forearm. About a case and review of literature. *Ann Chir Plast Esthet* (2017),<http://dx.doi.org/10.1016/j.anplas.2017.08.001>
2. Deger AN, Deger H, Tayfur M, Balcioglu MG, Kadioglu E. Acquired solitary glomangiomyoma on the forearm: a rare case report. *J Clin Diagn Res.* 2016;10(7). ED10e1.
3. Anthony R et al . An Extradigital Glomus Tumor of the Median Antebrachial Vein. *J Hand Surg Am.* 2018 Jan;43(1):88.e1-88.e4. doi: 10.1016/j.jhsa.2017.07.025. Epub 2017 Sep 6.
4. Venugopal PR. Extradigital Glomus Tumor-a Rare Cause for Undiagnosed Chronic Pain in Unusual Sites. *Indian J Surg.* 2015 Dec;77(Suppl 3):910-2. doi:10.1007/s12262-014-1062-1. Epub 2014 Apr 10.
5. Gill J, Van Vliet C. Infiltrating glomus tumor of uncertain malignant potential arising in the kidney. *Hum Pathol.* 2010;41:145-149.